

Case Report

Bilateral Additional Slips of Triceps Brachii Forming Osseo-Musculo-Fibrous Tunnels for Ulnar Nerves

Swamy RS, Rao MKG, Somayaji SN, Raghu J, Pamidi N

Department of Anatomy, Melaka Manipal Medical College, Manipal University, Manipal, Karnataka, India

Address for correspondence:

Dr. Mohandas KG Rao,
Department of Anatomy, Melaka
Manipal Medical College,
Manipal University, Manipal,
Karnataka - 576 104, India.
E-mail: mohandaskg@gmail.com

Abstract

Rare additional slips of triceps brachii muscle was found bilaterally in a sixty two year old South Indian male cadaver during routine dissection of upper limb for undergraduate students at Melaka-Manipal Medical College, Manipal University, Manipal, India. On left side, the variant additional muscle slip took origin from the lower part of the medial intermuscular septum about 4 cm proximal to the medial humeral epicondyle. From its origin, the muscle fibres were passing over the ulnar nerve and were joining the triceps muscle to get inserted to the upper surface of olecranon process of ulna. On right side, the additional muscle slip was larger and bulkier and was arising from the lower part of the medial border of the humerus about 4 cm proximal to the medial epicondyle in addition to its attachment to the medial intermuscular septum. On both sides, the additional slips were supplied by twigs from the radial nerve. On both sides, the ulnar nerve was passing between variant additional slip and the lower part of the shaft of the humerus in an osseo-musculo-fibrous tunnel. Such variant additional muscle slips may affect the function of triceps muscle and can lead to snapping of medial head of triceps and ulnar nerve over medial epicondyle and also can dynamically compress the ulnar nerve during the contraction of triceps leading to ulnar neuropathy around the elbow.

Keywords: Cubital tunnel syndrome, Nerve entrapment, Snapping triceps syndrome, Triceps brachii, Ulnar nerve

Introduction

Triceps brachii is a muscle of posterior compartment of the arm having medial, long and lateral heads and is an extensor of forearm at elbow joint. Its long head originates from the infraglenoid tubercle of the scapula, the lateral head from the area above to the radial groove of the humerus along with lateral intermuscular septum and the medial head from the area below to the radial groove and medial intermuscular septum. It is inserted on the upper surface of olecranon process of ulna and is supplied by radial nerve.^[1] Variations of triceps muscle are common. The present case is unique as it is bilateral and the variant additional slip is overlapping the ulnar nerve.

Case Report

During routine dissection for undergraduate students at department of anatomy, at our institution, we observed bilateral variation of triceps muscle in a South Indian male cadaver of a 62 year old. On left side, the variant additional slip of triceps muscle took origin from the lower part of the medial intermuscular septum, about 4 cm proximal to the medial epicondyle. From its origin, the muscle fibres were passing over the ulnar nerve and were joining the triceps muscle to get inserted on the upper surface of olecranon process of ulna [Figure 1]. On right side, the additional slip was larger and bulkier and in addition to its attachment to the medial intermuscular septum, it was arising from the lower part of the medial border of the humerus about 4 cm proximal to the medial epicondyle and then joined the triceps muscle, to get inserted on the upper surface of olecranon process of ulna [Figure 2]. The additional slips on both sides were supplied by twigs from the radial nerve.

On both sides, the ulnar nerve was passing between variant additional slip, medial intermuscular septum and the lower part of the shaft of the humerus in an osseo-musculo-fibrous

Access this article online

Quick Response Code:



Website: www.amhsr.org

DOI:
10.4103/2141-9248.117931

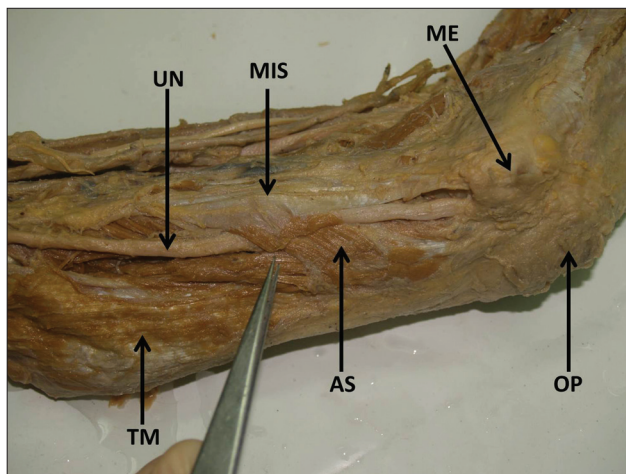


Figure 1: Dissection of Left arm showing the additional slip of triceps brachii (AS) taking origin from medial intermuscular septum (MIS) and joining the other heads of triceps brachii, overlapping the ulnar nerve (UN) creating an osseo-musculo-fibrous tunnel for the nerve. (ME-medial epicondyle; OP-olecranon process; TM-Triceps brachii muscle)

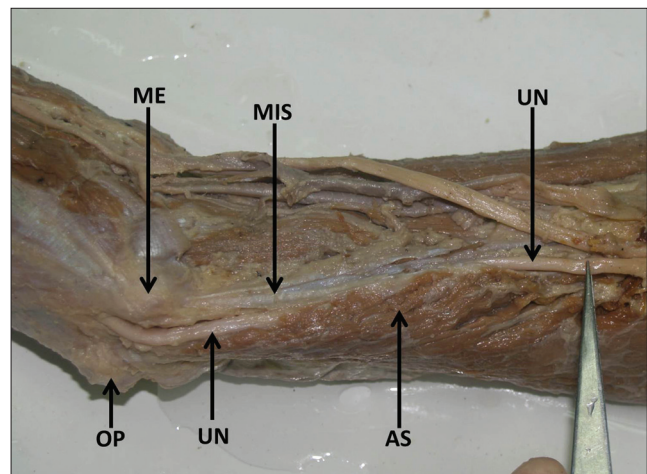


Figure 2: Dissection of right arm showing the additional slip of triceps brachii (AS) taking origin from MIS and lower part of medial border of humerus joining the other heads of triceps brachii. UN passing through an osseo-musculo-fibrous tunnel formed by the additional slip is also seen. (ME-medial epicondyle; OP-olecranon process)

tunnel and then was passing behind the medial epicondyle of humerus to enter the forearm [Figures 1 and 2].

Discussion

There are few reports available on additional heads of triceps brachii.^[2-5] Nayak *et al.*, have reported a case of unilateral fourth head of triceps brachii along with fourth head of biceps brachii.^[2] Tubbs *et al.*, reported similar case in which fourth head of triceps brachii originated from posterior aspect of surgical neck of the humerus.^[3] Fabrizio and Clemente have reported additional head of triceps which originated from proximal part of humerus.^[4] There are reports by Cheema and Singla about the fourth head of triceps brachii originating from the posteromedial aspect of humerus just below the surgical neck.^[5] The 'Struthers arcade' is a thin ligamentous structure or a thickening of the brachial fascia or muscle fibers of the medial head of the triceps muscle which extend to the medial intermuscular septum or a combination of above.^[6] The additional slips of triceps observed in the present case are different from the 'Struthers Arcade' as these slips are derived from intermuscular septa and are merging with triceps muscle to get inserted on the upper surface of olecranon process of ulna. In addition, these additional slips are distinct, prominent and bulky. When compared to previous reports, the present case is unique as the fourth head (additional slip) originates from medial intermuscular septum and overlaps the ulnar nerve and is bilateral. Additional slip may affect the function of triceps muscle in terms of its contractile power and direction of pull. Contraction of the additional slip might pull triceps medially resulting in snapping of triceps muscle over the medial epicondyle along with ulnar nerve, resulting in a condition called "snapping triceps syndrome".^[7-9] It has been reported that the ulnar nerve can get dynamically compressed during its course through the passage in between

the epitrochleoanconeus muscle and a prominent medial head of the triceps muscle.^[10,11] There are also reports of abnormal insertion of medial head of triceps muscle leading to symptoms similar to cubital tunnel syndrome.^[12] In the present case, compression of ulnar nerve can occur as it is passing in an osseo-musculo-fibrous tunnel leading to ulnar neuropathy around the elbow and clinical condition which may mimic the "cubital tunnel syndrome".

Conclusion

Though the additional heads of triceps brachii are reported before, seldom they are bilateral. Such additional slips may cause "snapping triceps syndrome" and may dynamically compress the ulnar nerve at the level of distal humerus leading to ulnar neuropathy around the elbow.

References

1. Standring S, Borley NR, Collins P, Crossman AR, Gatzoulis MA, Healy JC. Grey's anatomy: The anatomical basis of clinical practice. 40th ed. London: Elsevier, Churchill Livingstone; 2008. p. 826-37.
2. Nayak SR, Krishnamurthy A, Kumar M, Prabhu LV, Saralaya V, Thomas MM. Four headed biceps and triceps brachii muscles with neurovascular variation. *Anat Sci Int* 2007;83:107-11.
3. Tubbs RS, Salter EG, Oakes WJ. Triceps brachii muscle demonstrating a fourth head. *Clin Anat* 2006;19:657-60.
4. Fabrizio PA, Clemente FR. Variation in the triceps brachii muscle: A fourth muscular head. *Clin Anat* 1997;10:259-63.
5. Cheema P, Singla R. Four headed triceps brachii muscle. *Int J Anat Var* 2011;4:43-4.
6. Siqueira MG, Martins RS. The controversial arcade of Struthers. *Surg Neurol* 2005;64:17-21.
7. Jacobson JA, Jebson PJ, Jeffers AW, Fessell DP, Hayes CW. Ulnar nerve dislocation and snapping triceps syndrome:

- Diagnosis with dynamic sonography-report of three cases. Radiology 2001;220:601-5.
8. Matthias KD, Ghislain FA, Roger PV. Snapping triceps syndrome: A review of the literature. Shoulder and Elbow 2010;2:30-3.
 9. Spinner RJ, Goldner RD. Snapping of the medial head of the triceps and recurrent dislocation of the ulnar nerve. Anatomical and dynamic factors. J Bone Joint Surg Am 1998;80:239-47.
 10. O'Hara JJ, Stone JH. Ulnar nerve compression at the elbow caused by a prominent medial head of the triceps and an anconeus epitrochlearis muscle. J Hand Surg Br 1996;21:133-5.
 11. Gervasio O, Zaccone C. Surgical approach to ulnar nerve compression at the elbow caused by the epitrochleoanconeus muscle and a prominent medial head of the triceps. Neurosurgery 2008;62:186-93.
 12. Matsuura S, Kojima T, Kinoshita Y. Cubital tunnel syndrome caused by abnormal insertion of triceps brachii muscle. J Hand Surg Br 1994;19:38-9.

How to cite this article: Swamy RS, Rao M, Somayaji SN, Raghu J, Pamidi N. Bilateral additional slips of triceps brachii forming osseomusculo-fibrous tunnels for ulnar nerves. Ann Med Health Sci Res 2013;3:450-2.

Source of Support: Nil. **Conflict of Interest:** None declared.