

# Pharmacological Treatment of Uterine Fibroids

Moroni RM, Vieira CS, Ferriani RA, Candido-dos-Reis FJ, Brito LGO

Department of Gynecology and Obstetrics, Ribeirão Preto School of Medicine, University of São Paulo, São Paulo, Brazil

**Address for correspondence:**

Dr. Rafael Mendes Moroni,  
Bandeirantes Avenue, 3900,  
8<sup>th</sup> Floor, Monte Alegre, Ribeirão  
Preto, 14049-900, SP, Brazil.  
E-mail: [rafaelmmoroni@gmail.com](mailto:rafaelmmoroni@gmail.com)

## Abstract

Uterine fibroids (UF) are common, benign gynecologic tumors, affecting one in three to four women, with estimates of up to 80%, depending on the population studied. Their etiology is not well established, but it is under the influence of several risk factors, such as early menarche, nulliparity and family history. More than 50% of affected women are asymptomatic, but the lesions may be related to bothersome symptoms, such as abnormal uterine bleeding, pelvic pain and bloating or urinary symptoms. The treatment of UF is classically surgical; however, various medical options are available, providing symptom control while minimizing risks and complications. A large number of clinical trials have evaluated commonly used medical treatments and potentially effective new ones. Through a comprehensive literature search using PubMed, EMBASE, CENTRAL, Scopus and Google Scholar databases, through which we included 41 studies out of 7658 results, we thoroughly explored the different pharmacological options available for management of UF, their indications, advantages and disadvantages.

**Keywords:** Combined, Drug therapy, Fibroids, Gonadotropin-releasing hormone, Leiomyoma, Oral contraceptives, Progestins, Uterine

## Introduction

Uterine fibroids (UF), also known as uterine leiomyomata, are the most common benign gynecological tumors. It is estimated that they affect up to 80% of women by 50 years; however, the prevalence of symptomatic patients is much lower, reaching 20-30% of these women.<sup>[1]</sup> The etiology of UF is generally unknown, but many genetic, hormonal and biologic features of the disease have been described, contributing to its understanding. Predisposing factors generally overlap; nevertheless, it is assumed that the impact of each factor is related to its interference with the levels and metabolism of sex steroids and their metabolites.<sup>[2]</sup> Classically recognized risk factors are obesity,<sup>[3]</sup> a younger age at menarche,<sup>[4]</sup> nulliparity, black ethnicity<sup>[5]</sup> and age, with incidence peaking at the fourth decade.<sup>[6]</sup> Various symptoms are usually attributed to UF, such as abnormal uterine bleeding (AUB), pelvic pain and urinary symptoms, but there is no high quality data supporting these associations.<sup>[7]</sup> AUB has been shown in 64% of women with fibroids, compared with 28% of women without the disease,<sup>[8]</sup> whereas other

studies failed to demonstrate a relation between fibroids and a worse bleeding pattern.<sup>[9]</sup> Although observational studies on this matter frequently yield conflicting results, an interesting study on the relation of fibroids and endometrial function has shown defective decidualization and hemostasis in the endometrium of women with fibroids, suggesting a possible mechanism for the common clinical observation of increased bleeding in this group of women.<sup>[10]</sup> A higher incidence of severe dysmenorrhea has also not been demonstrated in women with fibroids, although dyspareunia and cyclic pelvic pain of moderate intensity were slightly increased.<sup>[11]</sup> For most women with leiomyomata, however, the association between symptoms and the disease is still a matter of debate.

Medical treatments may decrease symptoms potentially related to fibroids. Although most of them are not capable of treating the tumor itself and lead to marked decreases in fibroid volume, symptomatic control may still be achieved in many patients, who may prefer treating their conditions medically rather than resorting to invasive procedures. The objective of this narrative review is to gather the evidence supporting all the different medical treatments available for uterine leiomyomata, both classical and novel ones, trying to answer the recurring questions of whether they are effective or not for managing symptoms commonly attributed to fibroids. A summary of the medical treatments frequently used in clinical practice is presented in Table 1. Figure 1 proposes a medical management algorithm based on the discussions provided in this review.

**Access this article online**

**Quick Response Code:**



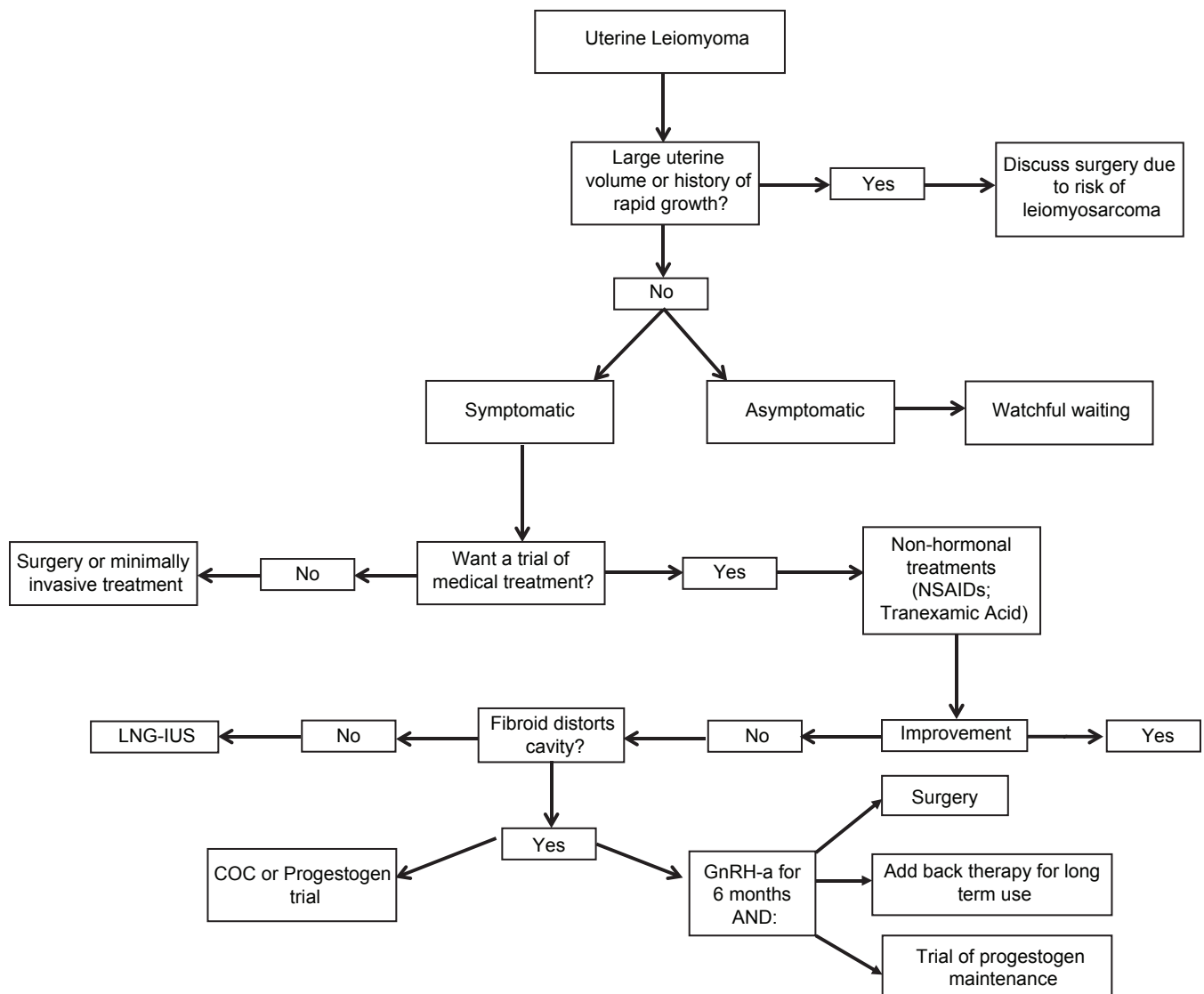
**Website:** [www.amhsr.org](http://www.amhsr.org)

**DOI:**  
10.4103/2141-9248.141955

**Table 1: Summary of medical treatments used in clinical practice for management of uterine leiomyomas**

Drug class	Action	Benefits	Risks	Side-effects (%)	Authors
COC	Inhibits ovulation; inhibits sex steroid secretion	17% decrease in the risk of leiomyoma growth; decreases bleeding and increases hematocrit	Thromboembolic events; hepatocellular adenoma (rare)	Spotting; mastalgia; headache; gastrointestinal upset	Qin <i>et al.</i> ; Orsini <i>et al.</i>
Progestogens	May inhibit ovulation and sex steroid synthesis; decidualizes endometrium, inducing a "pseudopregnancy" state	Improves bleeding in up to 70%; amenorrhea in up to 30%; may decrease uterine volume in up to 50%	Loss of bone mass (prolonged use of depot MPA)	Irregular bleeding/spotting; ovarian follicular cysts	Venkatachalam <i>et al.</i> ; Ichigo <i>et al.</i>
LNG-IUS	Endometrial atrophy	Reduces bleeding intensity in up to 99%; decreases uterine volume in about 40%	Device expulsion	Ovarian cysts; acne	Kriplani <i>et al.</i> ; Sayed <i>et al.</i>
GnRH-a	Hypoestrogenism due to gonadotrophin secretion inhibition	Uterine volume decrease in up to 50%; high rates of amenorrhea	Loss of bone mass with prolonged use	Hot flashes (>90%); vaginal atrophy; headache; mood disorders	Friedman <i>et al.</i> ; Tummon <i>et al.</i> ; Dawood <i>et al.</i>
SPRM	Inhibits ovulation; inhibits progesterone action on fibroid tissue	Improves bleeding in up to 98% of patients; decreases fibroid volume in up to 53%	Long term endometrial safety is unknown	Benign endometrial changes after short term use	Donnez <i>et al.</i> ; Williams <i>et al.</i>

NSAID: Non-steroid anti-inflammatory drugs, LNG-IUS: Levonorgestrel releasing intrauterine system, COC: Combined oral contraceptive, GnRH-a: Gonadotropin-releasing hormone analog, SPRM: Selective progesterone receptor modulators, MPA: Medroxyprogesterone acetate

**Figure 1:** Proposed algorithm for management of uterine leiomyomas, emphasizing medical treatment

## Methods of Literature Search

A comprehensive search in PubMed, EMBASE, CENTRAL, Scopus and Google Scholar databases was performed, starting at their inception. Key words used for searching were: (Fibroids OR leiomyoma OR leiom\* OR fibroid\*) AND (medical OR drug OR non-hormonal OR gonadotropin-releasing hormone (GnRH) OR gonadorelin OR levonorgestrel releasing intrauterine system (LNG-IUS) OR levonorgestrel OR progestogens OR progest\* OR mifepristone OR ulipristal OR asoprisnil OR selective progesterone receptor modulators (SPRM) OR raloxifene OR tamoxifen OR gestrinone). The search strategy retrieved 7658 results. Titles and abstracts were screened for studies of interest. Preference was given to large, randomized, controlled studies, but studies with other designs were also evaluated when higher quality evidence was not available. A total of 41 studies were selected for discussing the various treatment options, including randomized controlled trials (RCTs), prospective observational trials e retrospective studies.

## Expectant Management

The simplest management option upon the diagnosis of UF is clinical observation. As previously mentioned, a great proportion of women diagnosed with fibroids is asymptomatic. For such women, counseling regarding the benign nature of the disease and the possibility of expectantly managing the lesion without any intervention is almost always the best option.<sup>[12]</sup> There is no available method that can predict the lesions' potential for growth or for becoming symptomatic, but placebo arms of clinical trials involving women with UF have shown no significant change in uterine volume over 6-12 months of follow-up.<sup>[13]</sup> Expectant management can also be the best choice in women approaching the menopausal transition, since lesions usually decrease in volume and become asymptomatic after menopause.<sup>[7]</sup> Larger fibroids may also be followed without significant risk, but it is important to remind the patient that the risk of transformation to leiomyosarcoma, albeit low – 0,26% – exists.<sup>[14]</sup> The diagnosis of leiomyosarcoma among women is challenging, because clinical manifestations, such as a palpable abdominal mass, AUB and pelvic pain or pressure, usually overlap with those of leiomyomata. Rapid tumor growth is classically a suspicious sign for leiomyosarcoma and some authors consider volume doubling in 3-6 months a warning sign. Tumor features at imaging also provide some information, and novel techniques may facilitate distinction between benign and malignant cases. Two combined magnetic resonance imaging (MRI) techniques, diffusion-weighted imaging and apparent diffusion coefficient, have demonstrated high accuracy, with 100% sensitivity and specificity in a reported series.<sup>[15]</sup> Combining serum determination of lactate dehydrogenase (LDH) and its isozymes with MRI has also been shown as highly accurate.<sup>[16]</sup>

## Pharmacological Treatment

### Non-hormonal

Non-steroid anti-inflammatory drugs (NSAIDs) and antifibrinolytics are the non-hormonal alternatives used for treatment of UF. NSAIDs are commonly prescribed for the management of AUB, especially in cases with no identified organic pathology. For treatment of UF-related bleeding, however, evidence is scarce. A single RCT was able to detect a 36% decrease in non-organic AUB, but no consistent improvement in UF related bleeding.<sup>[17]</sup>

Tranexamic acid inhibits tissue plasminogen activator, which exerts fibrinolytic activity and degrades clots; the result is antifibrinolytic activity. Its efficacy in controlling UF-related bleeding is controversial<sup>[18]</sup> and it has also been related to a higher risk of fibroid necrosis and infarction (odds ratio [OR] = 3.6; 95% confidence intervals [CI] = 1.83-6.07).<sup>[19]</sup> Although there is a lack of high quality evidence, non-hormonal treatments are commonly used for symptomatic control during an acute UF-related uterine bleeding episode.

### Combined oral contraceptives

In the past, COCs were considered a risk factor for fibroid growth. Today, it is known that these risks are very unlikely and a meta-analysis of studies assessing the association of COCs to fibroid growth has demonstrated a 17% reduction in the risk of growth in current users, although the authors alerted for significant heterogeneity among included trials.<sup>[20]</sup> An RCT comparing COCs with a LNG-IUS for the treatment of fibroids has shown superiority of the LNG-IUS, but the COC still demonstrated improvement in menstrual blood loss and no significant change in the volume of the tumors.<sup>[21]</sup> An observational study of COC versus placebo has also shown a reduction of more than 2 days in menstrual bleeding and hematocrit improvement without changes in uterine volume.<sup>[22]</sup> Although there is a lack of robust evidence regarding the efficacy of these medications, a trial with COCs may still be effective in some women with fibroids.

### Oral and injectable progestogens

Although continuous systemic progestogens may be used in cases of non-organic AUB,<sup>[23]</sup> there is a lack of high quality evidence assessing the efficacy of these medications in treating AUB related to fibroids. In one study, trimestral depot medroxyprogesterone acetate (MPA) was used in twenty women with UF-related bleeding. After 6 months, 30% were amenorrheic, 70% had an improved bleeding pattern and 15% had an increase in hematocrit. Uterine and fibroid volumes were decreased by 48% and 33%, respectively.<sup>[24]</sup> Two other studies assessing the efficacy of oral progestogens in women with fibroids were located. One of them compared lynestrenol, an oral progestogen, with leuprolide, a GnRH agonist and demonstrated no significant difference between

the treatments in improving pelvic pain (risk ratio [RR] = 1.48, 95% CI = 0.59-3.71) and uterine bleeding (RR = 2.41, 95% CI = 0.90-6.49).<sup>[25]</sup> The other study, which included only 18 patients, compared dienogest, an oral progestagen, with leuprolide, demonstrating a significant decrease in tumor volume with both treatments (50% and 60%, respectively).<sup>[26]</sup> Norethisterone is another oral progestogen that is commonly used in resource-limited settings, in doses ranging from 15 mg to 30 mg daily. However, we could not find any evidence supporting such use. Treating fibroids with progestogens may be effective in some cases, but such treatment has been associated with histopathological changes that may be mistaken for leiomyosarcoma or smooth-muscle tumors of unknown malignant potential, such as an increase in cellularity and mitotic activity.<sup>[27]</sup> It is important, thus, to take into account a history of progestogen use when these changes are identified in the histopathological study of a fibroids specimen.

### Progestogen-releasing intrauterine system

The LNG-IUS was introduced as a contraceptive device, but it was recognized as an effective treatment for non-organic AUB, decreasing its intensity and improving anemia. Its use for treating UF-related bleeding, therefore, was soon investigated. A prospective study comparing the efficacy of the LNG-IUS in improving AUB in two groups of women, with and without fibroids, has demonstrated an 86% decrease in bleeding intensity in both groups. After 4 years, there was a 99.5% decrease in both groups and also a reduction in uterine volume in the group with fibroids.<sup>[28]</sup> Another study, an RCT comparing LNG-IUS with a low-dose COC in women with fibroids, demonstrated that the former was more effective in reducing UF-related bleeding than the latter, although the trial suffered with high attrition rates and assessed uterine bleeding in only 22 patients. In the LNG-IUS group, there was a significant decrease in menstrual blood loss and uterine volume, while hematocrit increased.<sup>[21]</sup> Both studies excluded women with submucous fibroids that caused distortion of the uterine cavity. Therefore, LNG-IUS is probably an effective option in selected symptomatic women with no endometrial distortion.<sup>[21,28]</sup>

### Antiprogesterones

Mifepristone, previously known as RU486, acts through inhibition of progesterone receptors, which seem to have a crucial role in the growth of UFs. Daily administration of mifepristone 5 mg and 10 mg has shown uterine volume reductions of 48% after 6 months and 52% after 1 year, for both doses. Amenorrhea occurred in 65% of women in 6 months and in 70% within 1 year.<sup>[29]</sup> A Cochrane systematic review demonstrated that mifepristone reduced UF-associated bleeding and improved fibroid-specific quality of life, without reducing fibroid volume.<sup>[30]</sup> Long-term use, however, is still controversial, due to the potential of inducing endometrial pathology.<sup>[29]</sup> Until long-term endometrial safety

is documented, the use of mifepristone for fibroid treatment must be viewed with caution.

### Gonadotropin-releasing hormone analogs

These molecules induce a state of hypoestrogenism due to inhibition of the gonadal axis, with consequent hypogonadism. Differently from COCs or progesterones, GnRH-a consistently decrease the volume of fibroid tumors and control symptoms. Initially, they increase gonadotropin secretion, a phenomenon known as flare-up effect, but after competing with the GnRH molecule, they cause a down-regulation of GnRH receptors. Another important mechanism is a decrease in the expression of several important effectors of fibroid growth (Insulin-like growth factor 1, epidermal growth factor and transforming growth factor-beta).<sup>[31]</sup>

The largest study evaluating UF volume reduction by GnRH-a used 3.75 mg of leuprolide acetate in monthly doses and has shown a 36% decrease in fibroid volume after 3 months, and a 45% decrease after 6 months. There was also a significant improvement in the hematocrit.<sup>[13]</sup> However, these drugs commonly lead to significant adverse effects, such as hot flashes, insomnia, mood disorders, sensation of vaginal dryness and headaches. Nevertheless, dropout rates before 12 weeks due to these adverse effects are low (6%). Loss of bone mineral density (BMD) is another important concern, since it is almost universal in postmenopausal hypoestrogenic women. Studies evaluating GnRH-a use for up to 6 months have not shown significant bone loss, and this time frame is usually considered safe.<sup>[32]</sup> However, 6 months after treatment withdrawal, BMD was only partially recovered in a study evaluating bone density after treatment with GnRH-a.<sup>[33]</sup>

Usually, these agents are used pre-operatively, with the aim of decreasing fibroid volume, improving hematocrit, reducing the need for blood transfusion and allowing for less invasive surgical techniques. A meta-analysis of 14 trials evaluating the use of these agents for 3-4 months before surgery has demonstrated diminished uterine and fibroid volumes, higher hematocrit levels and lower surgical and hospitalization times.<sup>[34]</sup> Furthermore, pre-operative use can convert an abdominal surgery into a vaginal one or avoid a midline abdominal incision.<sup>[34]</sup> However, there are possible disadvantages to pre-operative use, especially when myomectomy is the planned treatment, such as difficult enucleation of fibroids, loss of cleavage planes and higher risk of recurrence due to the reduction of previously small fibroids into surgically undetectable ones.<sup>[35]</sup> Other possible concerns are the possibility of delaying the diagnosis of leiomyosarcoma, a greater degree of tumor hyalinization and the risk of massive hemorrhage stemming from tumor degeneration.<sup>[36]</sup>

In an attempt to use GnRH-a as a long-term medical treatment for UF, concomitant use of hormone replacement regimens has been studied as a means of decreasing the hypoestrogenic adverse effects, a strategy known as add-back therapy.



Concurrent use of daily subcutaneous leuprolide and daily oral MPA versus leuprolide alone has demonstrated that only isolated leuprolide was associated with significant uterine volume reduction, whereas the combined group showed a reduction of only 14% after 6 months.<sup>[37]</sup> Conversely, there was a significant decrease in the incidence of hot flashes in the group that used combined MPA. Tibolone 2.5 mg has also been studied as add back therapy and it seems to be an effective option, since there was relief of hot flashes, lower bone loss and no decrease in treatment efficacy.<sup>[38]</sup> Other medications were also tested in small RCTs, such as progesterone, with indifferent results, raloxifen and combined estrogen-progesterones, with reduced bone loss.<sup>[7]</sup>

### GnRH antagonists

Differently from GnRH agonists, these drugs are not routinely used for the treatment of UF. The rationale for studying them was that the absence of an initial flare-up effect would lead to a more rapid decrease in uterine volume compared to GnRH-a. A randomized trial studied the effect of cetrorelix, a GnRH antagonist, versus placebo for 4 weeks prior to surgical treatment in 109 women, demonstrating a significant reduction in tumor volume (42.3% vs. 11.1%).<sup>[39]</sup> A smaller, open-label study including only 19 patients reported on the efficacy of ganirelix, another GnRH antagonist, in decreasing tumor volumes and demonstrated a significant reduction in a median of 19 days.<sup>[40]</sup> No trials assessing GnRH antagonists as long-term medical treatments for fibroids were located and pre-operative use still lacks high quality evidence.

### SPRM

SPRM are structurally similar to mifepristone, but have both agonist and antagonist actions. The two main drugs in this class are asoprisnil and ulipristal, with the latter already approved for pre-operative use in some countries. A randomized, multi-center trial including 129 women has demonstrated significant control of AUB after 12 weeks of treatment with asoprisnil, with improvements in 28-83% of the participants, according to the employed dose (5-25 mg, with the latter being the most effective). Fibroid volumes also decreased by 36%, and reported hypoestrogenic symptoms were minimal.<sup>[41]</sup> Ulipristal has been studied in a non-inferiority trial involving 307 women compared to leuprolide, a GnRH-a, in 5 mg and 10 mg dosages – a study titled PEARL II trial. After 3 months, there was an improvement in uterine bleeding in 90% of the 5 mg group, 98% of the 10 mg group and 89% of the leuprolide group. Fibroid volumes decreased by 36%, 42% and 53% in the three groups, respectively.<sup>[42]</sup> The same research group also compared ulipristal with placebo for pre-operative treatment of women with UF in the PEARL I trial. They reported effective control of uterine bleeding in 91% of the women receiving 5 mg and in 92% of those receiving 10 mg, versus 19% of those receiving placebo. Fibroid volumes also decreased up to 21%.<sup>[43]</sup> Both PEARL trials led to the

approval of ulipristal in the European Union as a pre-operative treatment of moderate to severe symptoms associated with UF. Long-term safety, however, is controversial for this class of drugs. In the PEARL II trial, only one woman, among 200 who received the medication, developed simple endometrial hyperplasia, but up to 59% of those who received ulipristal developed non-physiologic endometrial findings that appear to be specifically associated with the action of SPRMs,<sup>[44]</sup> compared to 12% of those who received leuprolide.<sup>[42]</sup> Another study with ulipristal, which enrolled 546 women, did not report any endometrial changes.<sup>[45]</sup>

Along with the antiprogestones, SPRMs are potentially effective medical treatments for fibroids. Safety concerns over prolonged use, however, exist and long term endometrial safety still needs to be ascertained before these agents can be employed as exclusively medical treatments. Pre-operative use, however, has been recognized as safe and effective.

### Selective estrogen receptor modulators

These molecules have agonist-antagonist activity on estrogen receptors (ER), with different actions across various estrogen-sensitive tissues. The main agents in this class are tamoxifen, frequently used in the treatment of breast cancer, and raloxifen, used as an antiresorptive drug in the treatment of osteoporosis. They have sparked interest in the treatment of leiomyoma due to their anti-estrogen potential. Tamoxifen has an agonist action on endometrial ERs and carries the risk of leading to endometrial pathology. Also, there are reports of significant leiomyoma growth in women with fibroids who used the drug for breast cancer treatment.<sup>[46]</sup> Raloxifen, on the other hand, has a more favorable profile, and a randomized clinical trial including 70 women with fibroids has shown volume reductions of 40% for up to 1 year of follow-up with the use of 60 mg daily. The study, however, only enrolled women who were postmenopausal, and it is not known whether this efficacy is maintained in premenopausal women.<sup>[47]</sup> There is no high quality evidence regarding the use of SERMs for treating fibroids.

### Aromatase inhibitors

These agents suppress the activity of the enzyme aromatase, responsible for the conversion of androgens into estrogens. It has been observed that UF cells may carry an intrinsic capacity of secreting estrogens due to the expression of aromatase, leading to the experimental use of this class of drugs in the treatment of UF. A randomized trial involving 60 premenopausal women with fibroids, comparing letrozole, an aromatase inhibitor, with triptorelin, a GnRH-a, has demonstrated significant decreases in tumor volumes for both drugs (45% vs. 33%).<sup>[48]</sup> No patient in the letrozole group, however, complained of hot flashes, while 96% in the GnRH-a group did. Another clinical trial, an open-label study involving 20 women with fibroids, studied the action of anastrozole on uterine volumes and on complaints of uterine bleeding

and dysmenorrhea, demonstrating a 9.3% volume reduction and a significant decrease in referred symptoms.<sup>[49]</sup> A study evaluating the effects of anastrozole over fibroid volumes and blood flow has also demonstrated a decrease in the volume of the tumors (40.9% reduction,  $P < 0.01$ ), but has shown no differences in Doppler parameters, suggesting a non-vascular mechanism of action for tumor volume reduction.<sup>[50]</sup> More robust evidence regarding the efficacy and safety of this class of drugs is still needed before they can be widely employed.

### Danazol

Danazol is a synthetic steroid, structurally similar to testosterone, which has an inhibitory action over sex-steroids synthesis and directly inhibits the progesterone receptor. It was more frequently used in the treatment of endometriosis, but its efficacy in the treatment of UF was assessed by some studies. A small study involving 20 women has demonstrated significant tumor volume reduction ( $23.6\% \pm 5\%$ ) and partial to complete symptomatic improvement, which persisted after 6 months of treatment withdrawal.<sup>[51]</sup> Higher quality studies, however, are lacking, and a systematic review from the Cochrane Collaboration could not find any RCTs that supported the efficacy of this treatment.<sup>[52]</sup> Besides, Danazol has significant adverse effects due to its androgenic action, including weight gain, acne and hirsutism.<sup>[53]</sup>

### Gestrinone

Gestrinone is a steroid with antiestrogenic and antiprogestogenic action, also used in the treatment of endometriosis. It has been studied for the treatment of UF in the past, with up to 60% reductions in fibroid volumes.<sup>[54]</sup> A more recently published, open-label study, which enrolled 16 women, has demonstrated amenorrhea in 69% of the participants after 6 months of treatment, together with tumor volume reductions of  $32\% \pm 10.8\%$ . As is the case for danazol, there is very little robust evidence to support the use of gestrinone in the treatment of fibroids.

## Conclusions

Treatment of UF must be individualized. A great proportion of women will be diagnosed with fibroids when seeking medical care for other complaints or when performing imaging studies for other indications. These women must be counseled on the characteristics of the disease, especially those who are asymptomatic. For women seeking treatment because of UF-related complaints, the nature and characteristics of the symptoms, the patient's age and the desire for future fertility must all be taken into account during treatment counseling. Fibroid volume, by itself, must not be considered an indication for surgical intervention and asymptomatic women may need nothing more than regular reevaluation. Large fibroids, however, deserve attention, especially if rapid growth has occurred. There is no consensus on whether patients with large and rapidly growing nodules should always receive

surgical treatment, despite the absence of symptoms. Imaging techniques and LDH dosage may assist in decision-making.

GnRH-a are the most effective medications to improve symptoms and decrease tumor volumes, but side effects and a maximum length of safe use limit their clinical application. Strategies involving long-term use of GnRH-a with add-back therapy may be offered to patients with good responses to avoid a surgical intervention. There is limited evidence on the effect of COCs and progestagens, but published studies have shown slightly reduced uterine volumes and improved bleeding patterns. These drugs may be an interesting initial choice due to their potential benefit, low cost and relative safety. LNG-IUS may be offered as an effective option for managing bleeding in women with non-submucosal fibroids. Short term use of SPRMs is safe and ulipristal has already been approved for pre-operative treatment of UF in some locations. Long term use of SPRMs and antiprogestogens both show promising results as effective long-term medical treatments for fibroids. Endometrial safety after prolonged use, however, is still a concern for these agents. Experimental therapies, such as aromatase inhibitors and SERMS, still have little applicability in the clinical setting.

Pharmacological treatment of UF should always be considered when counseling women on the potential strategies for addressing fibroid-related complaints. Many women will prefer long-term medication use over some form of invasive treatment. Published evidence supports the efficacy of many agents for symptomatic control and a trial of medical treatment in selected and motivated patients may obviate the need for surgery.

## References

1. Baird DD, Dunson DB, Hill MC, Cousins D, Schectman JM. High cumulative incidence of uterine leiomyoma in black and white women: Ultrasound evidence. *Am J Obstet Gynecol* 2003;188:100-7.
2. Flake GP, Andersen J, Dixon D. Etiology and pathogenesis of uterine leiomyomas: A review. *Environ Health Perspect* 2003;111:1037-54.
3. Lumbiganon P, Rungpa S, Phandhu-fung S, Laopaiboon M, Vudhikamraksa N, Werawatakul Y. Protective effect of depot-medroxyprogesterone acetate on surgically treated uterine leiomyomas: A multicentre case – Control study. *Br J Obstet Gynaecol* 1996;103:909-14.
4. Marshall LM, Spiegelman D, Goldman MB, Manson JE, Colditz GA, Barbieri RL, *et al.* A prospective study of reproductive factors and oral contraceptive use in relation to the risk of uterine leiomyomata. *Fertil Steril* 1998;70:432-9.
5. Taioli E, Garte SJ, Trachman J, Garbers S, Sepkovic DW, Osborne MP, *et al.* Ethnic differences in estrogen metabolism in healthy women. *J Natl Cancer Inst* 1996;88:617.
6. Parazzini F, La Vecchia C, Negri E, Cecchetti G, Fedele L. Epidemiologic characteristics of women with uterine fibroids: A case-control study. *Obstet Gynecol* 1988;72:853-7.
7. Lethaby A, Vollenhoven B. Fibroids (uterine myomatosis,

- leiomyomas). *Clin Evid* (Online) 2011;2011:0814.
8. Wegienka G, Baird DD, Hertz-Picciotto I, Harlow SD, Steege JF, Hill MC, *et al.* Self-reported heavy bleeding associated with uterine leiomyomata. *Obstet Gynecol* 2003;101:431-7.
9. Marino JL, Eskenazi B, Warner M, Samuels S, Vercellini P, Gavoni N, *et al.* Uterine leiomyoma and menstrual cycle characteristics in a population-based cohort study. *Hum Reprod* 2004;19:2350-5.
10. Sinclair DC, Mastroyannis A, Taylor HS. Leiomyoma simultaneously impair endometrial BMP-2-mediated decidualization and anticoagulant expression through secretion of TGF- $\beta$ 3. *J Clin Endocrinol Metab* 2011;96:412-21.
11. Lippman SA, Warner M, Samuels S, Olive D, Vercellini P, Eskenazi B. Uterine fibroids and gynecologic pain symptoms in a population-based study. *Fertil Steril* 2003;80:1488-94.
12. Divakar H. Asymptomatic uterine fibroids. *Best Pract Res Clin Obstet Gynaecol* 2008;22:643-54.
13. Friedman AJ, Hoffman DI, Comite F, Browneller RW, Miller JD. Treatment of leiomyomata uteri with leuprolide acetate depot: A double-blind, placebo-controlled, multicenter study. The Leuprolide Study Group. *Obstet Gynecol* 1991;77:720-5.
14. Parker WH, Fu YS, Berek JS. Uterine sarcoma in patients operated on for presumed leiomyoma and rapidly growing leiomyoma. *Obstet Gynecol* 1994;83:414-8.
15. Namimoto T, Yamashita Y, Awai K, Nakaura T, Yanaga Y, Hirai T, *et al.* Combined use of T2-weighted and diffusion-weighted 3-T MR imaging for differentiating uterine sarcomas from benign leiomyomas. *Eur Radiol* 2009;19:2756-64.
16. Goto A, Takeuchi S, Sugimura K, Maruo T. Usefulness of Gd-DTPA contrast-enhanced dynamic MRI and serum determination of LDH and its isozymes in the differential diagnosis of leiomyosarcoma from degenerated leiomyoma of the uterus. *Int J Gynecol Cancer* 2002;12:354-61.
17. Ylikorkala O, Pekonen F. Naproxen reduces idiopathic but not fibromyoma-induced menorrhagia. *Obstet Gynecol* 1986;68:10-2.
18. Naoulou B, Tsai MC. Efficacy of tranexamic acid in the treatment of idiopathic and non-functional heavy menstrual bleeding: A systematic review. *Acta Obstet Gynecol Scand* 2012;91:529-37.
19. Ip PP, Lam KW, Cheung CL, Yeung MC, Pun TC, Chan QK, *et al.* Tranexamic acid-associated necrosis and intralesional thrombosis of uterine leiomyomas: A clinicopathologic study of 147 cases emphasizing the importance of drug-induced necrosis and early infarcts in leiomyomas. *Am J Surg Pathol* 2007;31:1215-24.
20. Qin J, Yang T, Kong F, Zhou Q. Oral contraceptive use and uterine leiomyoma risk: A meta-analysis based on cohort and case-control studies. *Arch Gynecol Obstet* 2013;288:139-48.
21. Sayed GH, Zakherah MS, El-Nashar SA, Shaaban MM. A randomized clinical trial of a levonorgestrel-releasing intrauterine system and a low-dose combined oral contraceptive for fibroid-related menorrhagia. *Int J Gynaecol Obstet* 2011;112:126-30.
22. Orsini G, Laricchia L, Fanelli M. Low-dose combination oral contraceptives use in women with uterine leiomyomas. *Minerva Ginecol* 2002;54:253-61.
23. Hubacher D, Lopez L, Steiner MJ, Dorflinger L. Menstrual pattern changes from levonorgestrel subdermal implants and DMPA: Systematic review and evidence-based comparisons. *Contraception* 2009;80:113-8.
24. Venkatachalam S, Bagratee JS, Moodley J. Medical management of uterine fibroids with medroxyprogesterone acetate (Depo Provera): A pilot study. *J Obstet Gynaecol* 2004;24:798-800.
25. Verspyck E, Marpeau L, Lucas C. Leuprolerin depot 3.75 mg versus lynestrenol in the preoperative treatment of symptomatic uterine myomas: A multicentre randomised trial. *Eur J Obstet Gynecol Reprod Biol* 2000;89:7-13.
26. Ichigo S, Takagi H, Matsunami K, Suzuki N, Imai A. Beneficial effects of dienogest on uterine myoma volume: A retrospective controlled study comparing with gonadotropin-releasing hormone agonist. *Arch Gynecol Obstet* 2011;284:667-70.
27. Boyd C, McCluggage WG. Unusual morphological features of uterine leiomyomas treated with progestogens. *J Clin Pathol* 2011;64:485-9.
28. Kriplani A, Awasthi D, Kulshrestha V, Agarwal N. Efficacy of the levonorgestrel-releasing intrauterine system in uterine leiomyoma. *Int J Gynaecol Obstet* 2012;116:35-8.
29. Eisinger SH, Bonfiglio T, Fiscella K, Meldrum S, Guzik DS. Twelve-month safety and efficacy of low-dose mifepristone for uterine myomas. *J Minim Invasive Gynecol* 2005;12:227-33.
30. Tristan M, Orozco LJ, Steed A, Ramírez-Morera A, Stone P. Mifepristone for uterine fibroids. *Cochrane Database Syst Rev* 2012;8:CD007687.
31. Gutmann JN, Corson SL. GnRH agonist therapy before myomectomy or hysterectomy. *J Minim Invasive Gynecol* 2005;12:529-37.
32. Tummon IS, Ali A, Pepping ME, Radwanska E, Binor Z, Dmowski WP. Bone mineral density in women with endometriosis before and during ovarian suppression with gonadotropin-releasing hormone agonists or danazol. *Fertil Steril* 1988;49:792-6.
33. Dawood MY, Lewis V, Ramos J. Cortical and trabecular bone mineral content in women with endometriosis: Effect of gonadotropin-releasing hormone agonist and danazol. *Fertil Steril* 1989;52:21-6.
34. Lethaby A, Vollenhoven B, Sowter M. Efficacy of pre-operative gonadotrophin hormone releasing analogues for women with uterine fibroids undergoing hysterectomy or myomectomy: A systematic review. *BJOG* 2002;109:1097-108.
35. Farquhar C, Brown PM, Furness S. Cost effectiveness of pre-operative gonadotrophin releasing analogues for women with uterine fibroids undergoing hysterectomy or myomectomy. *BJOG* 2002;109:1273-80.
36. Mettler L, Schollmeyer T, Tinelli A, Malvasi A, Alkatout I. Complications of uterine fibroids and their management, surgical management of fibroids, laparoscopy and hysteroscopy versus hysterectomy, haemorrhage, adhesions, and complications. *Obstet Gynecol Int* 2012;2012:791248.
37. Friedman AJ, Barbieri RL, Doubilet PM, Fine C, Schiff I. A randomized, double-blind trial of a gonadotropin releasing-hormone agonist (leuprolide) with or without medroxyprogesterone acetate in the treatment of leiomyomata uteri. *Fertil Steril* 1988;49:404-9.
38. Morris EP, Rymer J, Robinson J, Fogelman I. Efficacy of tibolone as "add-back therapy" in conjunction with a



- gonadotropin-releasing hormone analogue in the treatment of uterine fibroids. *Fertil Steril* 2008;89:421-8.
39. Engel JB, Audebert A, Frydman R, Zivny J, Diedrich K. Presurgical short term treatment of uterine fibroids with different doses of cetrorelix acetate: A double-blind, placebo-controlled multicenter study. *Eur J Obstet Gynecol Reprod Biol* 2007;134:225-32.
  40. Flierman PA, Oberyé JJ, van der Hulst VP, de Blok S. Rapid reduction of leiomyoma volume during treatment with the GnRH antagonist ganirelix. *BJOG* 2005;112:638-42.
  41. Chwalisz K, Larsen L, Mattia-Goldberg C, Edmonds A, Elger W, Winkel CA. A randomized, controlled trial of asoprisnil, a novel selective progesterone receptor modulator, in women with uterine leiomyomata. *Fertil Steril* 2007;87:1399-412.
  42. Donnez J, Tomaszewski J, Vázquez F, Bouchard P, Lemieszczuk B, Baró F, *et al.* Ulipristal acetate versus leuprolide acetate for uterine fibroids. *N Engl J Med* 2012;366:421-32.
  43. Donnez J, Tatarchuk TF, Bouchard P, Puscasiu L, Zakharenko NF, Ivanova T, *et al.* Ulipristal acetate versus placebo for fibroid treatment before surgery. *N Engl J Med* 2012;366:409-20.
  44. Mutter GL, Bergeron C, Deligdisch L, Ferenczy A, Glant M, Merino M, *et al.* The spectrum of endometrial pathology induced by progesterone receptor modulators. *Mod Pathol* 2008;21:591-8.
  45. Williams AR, Bergeron C, Barlow DH, Ferenczy A. Endometrial morphology after treatment of uterine fibroids with the selective progesterone receptor modulator, ulipristal acetate. *Int J Gynecol Pathol* 2012;31:556-69.
  46. Le Bouëdec G, de Latour M, Dauplat J. Expansive uterine myoma during tamoxifen therapy. 11 cases. *Presse Med* 1995;24:1694-6.
  47. Palomba S, Orio F Jr, Morelli M, Russo T, Pellicano M, Zupi E, *et al.* Raloxifene administration in premenopausal women with uterine leiomyomas: A pilot study. *J Clin Endocrinol Metab* 2002;87:3603-8.
  48. Parsanezhad ME, Azmoon M, Alborzi S, Rajaeefard A, Zarei A, Kazerooni T, *et al.* A randomized, controlled clinical trial comparing the effects of aromatase inhibitor (letrozole) and gonadotropin-releasing hormone agonist (triptorelin) on uterine leiomyoma volume and hormonal status. *Fertil Steril* 2010;93:192-8.
  49. Hilário SG, Bozzini N, Borsari R, Baracat EC. Action of aromatase inhibitor for treatment of uterine leiomyoma in perimenopausal patients. *Fertil Steril* 2009;91:240-3.
  50. Brito LG, Candido-dos-Reis FJ, Magario FA, Sabino-de-Freitas MM. Effect of the aromatase inhibitor anastrozole on uterine and leiomyoma Doppler blood flow in patients scheduled for hysterectomy: A pilot study. *Ultrasound Obstet Gynecol* 2012;40:119-20.
  51. De Leo V, la Marca A, Morgante G. Short-term treatment of uterine fibromyomas with danazol. *Gynecol Obstet Invest* 1999;47:258-62.
  52. Ke LQ, Yang K, Li J, Li CM. Danazol for uterine fibroids. *Cochrane Database Syst Rev* 2009;(3):CD007692.
  53. Telimaa S, Puolakka J, Rönnerberg L, Kauppila A. Placebo-controlled comparison of danazol and high-dose medroxyprogesterone acetate in the treatment of endometriosis. *Gynecol Endocrinol* 1987;1:13-23.
  54. Coutinho EM. Treatment of large fibroids with high doses of gestrinone. *Gynecol Obstet Invest* 1990;30:44-7.

**How to cite this article:** Moroni RM, Vieira CS, Ferriani RA, Candido-dos-Reis FJ, Brito L. Pharmacological treatment of uterine fibroids. *Ann Med Health Sci Res* 2014;4:185-92.

**Source of Support:** We would like to thank the National Council for Scientific and Technological Development (CNPq – Brazil) for the support provided during the completion of this work (Process Number 477492/2012-6). **Conflict of Interest:** None declared.