

Giant Meckel's Diverticulum with "Daughter"/"Grand-daughter" Diverticula: An "On-Table" Surprise at an Acute Abdomen

Sir,

Meckel's diverticulum (MD) is one of the common entities tackled by a general surgeon. Although it has an array of clinical presentations, we came across an unusual intraoperative finding that surprised us on the operating table during an emergency abdominal exploration. The purpose of this paper is to make the surgical fraternity aware of such an atypical, however, clinically relevant finding and to highlight the significance of early surgical intervention in these cases. To the best of our knowledge, such a case is yet to be reported.

A 35-year-old male was referred to us from another hospital with a 2-day history of acute-onset generalized colicky abdominal pain, recurrent bilious vomiting, abdominal distension and inability to pass stools and flatus. His dehydration and electrolyte imbalances were corrected before he was admitted with us. He was afebrile with normal vital parameters. The hemogram and the blood-biochemistry reports at our institute were within the normal limits. Abdominal X-ray was suggestive of acute small intestinal obstruction. Contrast-enhanced computerized tomography, however, was unable to pin-point the etiology [Figure 1]. His subsequent emergent exploratory laparotomy revealed markedly dilated small-bowel without any peritoneal contamination. Although the appendix was normal, there was a giant inflamed MD with torsion leading to small bowel obstruction. On adhesiolysis, we were surprised to note a strikingly unusual finding; there were multiple "daughter"/"grand-daughter" diverticula arising from the MD [Figure 2]. Presence or otherwise of any ectopic tissue at the base of the MD could not be plausibly excluded by clinical palpation. He underwent the standard segmental ileal resection-anastomosis and recovered well afterwards. Subsequent histopathological examination confirmed Meckel's diverticulitis with thinned-out mucosa at the sites of "grand-daughter" diverticula. However, it did not reveal any ectopic tissue at the base.

As is well-known, the omphalo-mesenteric duct remnants occur in 2% population;^[1] and MD is the most common of them all.^[2] The list of salient complications of MD comprises

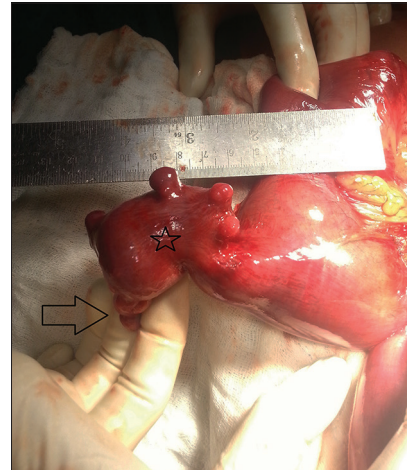


Figure 1: Giant inflamed Meckel's diverticulum (*) with "daughter" and "grand-daughter" diverticula (arrow)

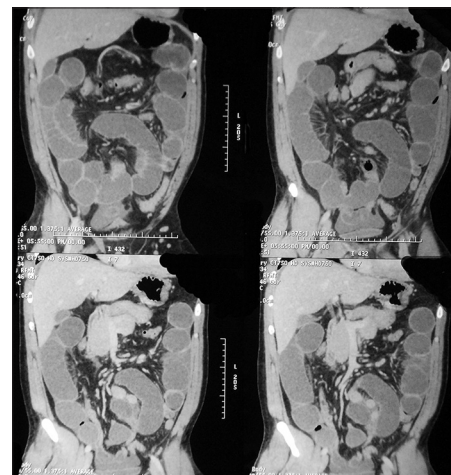


Figure 2: Coronal computed tomography of abdomen. Note the dilated fluid-filled small bowel loops suggesting acute intestinal obstruction. Meckel's diverticulum could not be identified

intestinal obstruction, ulceration, gastro-intestinal hemorrhage, diverticulitis, perforation, and intussusception.^[3] Adults with MD are generally asymptomatic.^[4] However, recently, there seems to be an addition to the existing list of MD's complications/sequel wherein an interesting finding of "daughter" diverticula arising from the "mother" MD was reported for the first time in the literature.^[5] Although, the co-relation is yet to be convincingly established, it seems logical that the mucosal thinning at these "daughter" diverticula puts the patient under great risk of early perforation and subsequent peritonitis at an acute setting, especially in a "torted" MD (like in our case) causing the "closed-loop" effect. In this context, our case depicts atypical diverticular outpunchings arising from the "daughter" diverticula. This further underscores the significance of early intervention in a case of an acute intestinal obstruction with MD as the suspected etiology. Utilizing the conceptual basis behind the accepted terminology – the "daughter" hydatid cysts, we labeled this unique finding as the "grand-daughter" diverticula.

To conclude, we feel that, any emergency surgical team dealing with abdominal emergencies should be aware of such pathology (though rare) to avoid surgical-table surprises that happened to us in this case. Furthermore, it sounds rational to recommend excision of such an MD even when its “grand-daughter” diverticula are incidentally diagnosed and have remained clinically silent.

**Jategaonkar PA, Jategaonkar SP¹,
Yadav SP²**

*Department of Minimal Access/GI Surgery,
Krishna Institute of Medical Sciences Deemed University,
Malkapur, Karad (Dist. Satara), ¹Department of Pediatrics,
Mahatma Gandhi Institute of Medical Sciences, Sevagram,
Wardha, ²Department of General/Laparoscopic Surgery,
Hinduja Health Care Surgical, Mumbai, Maharashtra, India
E-mail: jategaonkarpa@gmail.com*

References

1. Ioannidis O, Paraskevas G, Kakoutis E, Kotronis A, Papadimitriou N, Chatzopoulos S, *et al.* Coexistence of

multiple omphalomesenteric duct anomalies. *J Coll Physicians Surg Pak* 2012;22:524-6.

2. Aydoğan F, Aytaç E, Durak H. A rare cause of palpable mass located at the suprapubic area: Abscess of omphalomesenteric duct cyst. *Turk J Gastroenterol* 2010;21:195-6.
3. Bouassida M, Mighri MM, Trigui K, Chtourou MF, Sassi S, Feidi B, *et al.* Meckel's diverticulum: An exceptional cause of vesicoenteric fistula: Case report and literature review. *Pan Afr Med J* 2013;15:9.
4. Sawada F, Yoshimura R, Ito K, Nakamura K, Nawata H, Mizumoto K, *et al.* Adult case of an omphalomesenteric cyst resected by laparoscopic-assisted surgery. *World J Gastroenterol* 2006;12:825-7.
5. Singla SL, Garg P, Singh B. Daughter diverticula from Meckel's diverticulum. *Indian J Gastroenterol* 1997;16:69-70.

Access this article online

Quick Response Code:



Website: www.amhsr.org

DOI:
10.4103/2141-9248.138051