

Patients Undergoing Dacryocystorhinostomy Surgery in Northern Iran: An Epidemiologic Study

Majidaee M, Mohammadi M, Sheikh Rezaee MR¹, Khademlu M¹, Heidari Gorji MA²

Bu Ali Hospital, ¹Departments of Medicine and ²Nursing, Mazandaran University of Medical Science, Sari, Iran

Address for correspondence:
Prof. Mohammad Ali Heidari Gorji,
Department of Nursing and
Midwifery, Vesal Street, Amir
Mazandarani Boulevard, Sari, Iran.
E-mail: gorjim29@yahoo.com

Abstract

Background: Dacryocystorhinostomy (DCR) is widely accepted as the procedure of choice for surgical correction of lacrimal drainage system obstruction distal to common canaliculus in adulthood. Although, there are only limited epidemiological data available in Iran about the patients undergoing DCR surgery. **Aim:** This study was aimed to survey the demographic characteristics of patients received (DCR) surgery to achieve the newer information about these patients. **Subjects and Methods:** In this descriptive study, the demographic characters such as age, and gender, clinical findings, history of surgery, etc., extracted from archived files of the patients undergoing DCR surgery in educational and treatment center of Bu Ali Sina Hospital in Mazandaran. Data were entered into the SPSS software version 15 (Chicago, IL, USA) and analysis inferential analysis performed using t-test and Chi-square. **Results:** Among 40 under survey records 72.5% (29/40) were female and 27.5% (11/40) male. Patient's mean age was 48.22 (17.1). Fifty percent were from a rural area and there was a significant relationship between gender and dacryocystitis rate, it was high among female ($P = 0.02$) (Most of the patients complained of tearing 87.5% (35/40) and recurrent attacks of acute dacryocystitis 70.3% (28/40), respectively. Conjunctivitis in 33.3% (13/40) of patients and chronic discharge was seen in 40% (16/40) of cases. **Conclusion:** Overall finding showed in comparisons of men with the females of middle age and above included higher cases of dacryocystitis. The authors suggest regarding high prevalence of sinusitis and allergies in Northern Iran, checking by ENT specialist is beneficial to exact diagnosis and programming for treatment of this kind of patients.

Keywords: Dacryocystitis, Dacryocystorhinostomy surgery, Mucopurulent, Nasolacrimal duct obstruction, Tearing

Introduction

Nasolacrimal duct obstruction (NLDO) is the obstruction of nasolacrimal duct and included two types of congenital or acquired. Obstruction of the nasolacrimal duct is the cause of the excess overflow of tears called Epiphora.^[1] A disorder of the tear drainage is either functional or anatomical abnormalities. In terms of functional disorder, pumping dysfunction is the problem, which may be due to poor function of lacrimal punctum, eyelid laxity or orbicularis muscle weakness or facial nerve palsy. In the anatomic blockage, congenital or acquired disorders can occur at any point along the lacrimal

drainage. Congenital blockage of the lacrimal drainage system, usually occur by Hasner membrane valve, which covers the end of the nasolacrimal duct. Acquired blockage is due to naso-orbital trauma, chronic sinusitis, lacrimal sac neoplasms, dacryocystitis, and evolutionary stenosis.^[2] In both kinds of disorder, excessive tearing is the main complain about patients with NLDO and pain at the side of the nose suggests dacryocystitis.

A dacryocystorhinostomy (DCR) is the treatment of choice for most patients with acquired NLDO for managing Epiphora due to NLDO. It is a procedure that creates an anastomosis between the lacrimal sac and nasal mucosa through a bony ostium.^[3] Surgical indications include recurrent dacryocystitis, chronic mucoid reflux, painful distension of the lacrimal sac, and bothersome Epiphora.

DCR suggests two methods of surgery: External DCR and endoscopic endonasal DCR for acquiring NLDO, which same success rate reported for both methods.^[4] The reported

| Access this article online | |
|--|--|
| Quick Response Code:  | Website: www.amhsr.org |
| | DOI: 10.4103/2141-9248.133461 |

success rates of both procedures range from 63% to 97%.^[5] A satisfactory procedure is defined as freedom from Epiphora at 3 months after surgery and a healed patent neo-ostium with a free flow of tears from the conjunctiva to the nose.^[6] The wide range of success is likely due to surgical variability, patient demographics, and lack of standardized outcome measures in the medical literature.^[4] Although some time epidemiologic characters also involved in the rate of surgery success. Prakash *et al.* in their study have reported that there are distinct patterns of geographical variation in terms of the etiology, according to the local climate in infective keratitis and also in microbial conjunctivitis.^[7] For example, a study reviewed the cases through an epidemiologic survey of chronic dacryocystitis on 662 patients with chronic dacryocystitis by Badhu *et al.* In Nepal, finding showed in 13% (86) of them were from the high hills of Nepal and 87% from low subtropical areas. Chronic dacryocystitis is more common in the subtropical plains of Nepal with a monsoon climate than in the high hills.^[8] Hence, an understanding of the epidemiologic characters is important for the management of this disease. It is highlighting the needs for epidemiological researches in different geographical areas. As author knowledge, there is no study conducted in northern Iran to report the epidemiologic characters of patients received DCR surgery. Considering extracting native epidemiologic information helps in diagnosis and treatment which plays an important role in reducing complications and health-care costs. Therefore, this study aimed to survey the epidemiology and demographic characteristics of patients received DCR surgery.

Materials and Methods

In this descriptive study, first proposal approved by the Research Ethics Committee of Mazandaran University of Medical Sciences - Bu Ali Sina Hospital in Sari 2008-2009. The patients who participated in this study signed a consent form. According to study, the aim archived recorded files of patients who underwent DCR surgery due to nasolacrimal duct blockage were extracted and evaluated. The researchers explored records of patient demographic characteristics such as age, and gender, occupation, residence and clinical findings such as tearing, conjunctivitis, pain, chronic mucous discharge and previous history of repeated attacks of acute dacryocystitis and the history of DCR surgery. The inclusion criteria included: The 1st time referred patients to eye DCR surgery in Bu Ali Sina Center, the exclusion criteria were incompletely recorded files in terms of required information. The acquired data were entered into the SPSS software version 15 (Chicago, IL, USA), and analyzed inferentially by t-test and Chi-square. $P < 0.05$ were considered as significant.

Results

Of 40 cases, 72.5% (29/40) were females and 27.5% (11/40) male. Mean age was 48.2 (17.1). Fifty percent 20/40 of patients were living in rural and the rest in urban areas. In terms of jobs

12.5% (5/40) were farmer, 79.5% (29/40) patient's housewives and 15% (6/40) were self-employed. The results of t-test showed a significant relationship between the genders and rates of dacryocystitis ($P = 0.02$ [Figure 1]).

Among 29 under survey women, 44.8% (13/40) were on menopause stage. Most patients complain of tearing 87.5% (35/40) and recurrent attacks of acute dacryocystitis 70.3% (28/40) respectively. Mostly involved eye was left eye 52.5% (21/40).

Frequency distribution of patients based on the clinical symptoms dacryocystitis and some demographic characteristics are given in Table 1. There was no significant relationship between gender and recurrent dacryocystit attacks ($P = 0.3$). Furthermore, a significant relationship was not found between location and recurrent dacryocystit attacks ($P = 0.7$).

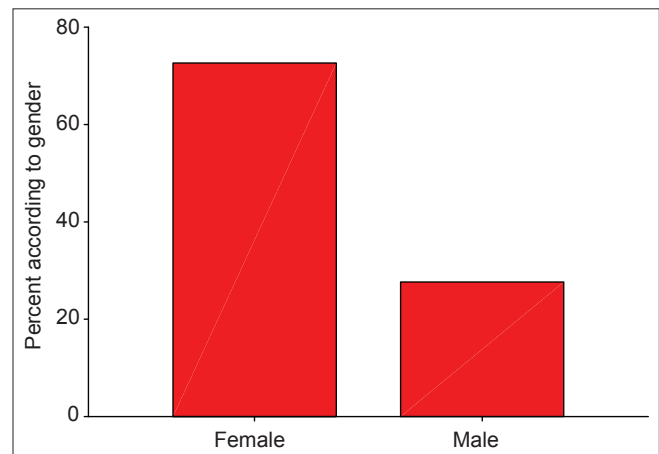


Figure 1: The relationship between gender and prevalence of dacryocystitis

Table 1: Distribution according to some demographic and clinical characteristics of patients with dacryocystitis

| Variable | Percentage | Frequency |
|-------------------------------------|------------|-----------|
| Age | | |
| 30> | 12.5 | 5 |
| 50-30 | 40 | 16 |
| 50< | 47.5 | 19 |
| Gender | | |
| Female | 72/5 | 29 |
| Male | 27.5 | 11 |
| Tearing | 87.5 | 35 |
| Conjictiotyt | 33.3 | 13 |
| Pain | 15.4 | 6 |
| Chronic mucous secretions | 40 | 16 |
| Frequency of dacryocystitis attacks | 70.3 | 26 |
| Eye involvement | | |
| Right | 37.5 | 15 |
| Left | 52.5 | 21 |
| Bilateral involvement | 10 | 4 |
| History of DCR surgery DCR | 7.5 | 3 |

DCR: Dacryocystorhinostomy

Discussion

Epiphora or tearing is the main complaint of referring patients to eye clinics^[2] and the major cause of tearing in adults is the primary blockage of nasolacrimal duct, which can cure through DCR surgery. In the current study, the main complaint of patients was shedding tears (87.5%), which was in consonance with the results of Ferdosi *et al.*^[9] In this study, 72.5% of patients were female and 27.5% male who found similar results in most studies.^[10,11] Gilliland *et al.*, believed the predilection in females may be due to the smaller nasolacrimal canal diameter in females than in men and hormonal factors.^[12] About 47.5% of patients in this study were in the age group above 50 years, which is in harmony with Yoon *et al.*, study^[13] and 44.8% of female cases were in menopause stage, this finding confirms the prevalence of this disorder in women in the menopause stage.^[14] In this study, the greatest involvement consisted the left eye and a bilateral involvement has been minimal. In Ivanišević *et al.* study the analysis of 91 patients with primary acquired blockage of nasolacrimal duct was occurring mostly in the left eye (53.8%) and lowest two-sided involvement (6.6%) respectively.^[15] In Prakash *et al.*, study also there was a relatively high incidence of the disease on the left side (40%) when compared with the right side (32%). In general, the disease had predilection to the left side, especially in females, because of their narrow bony canal. The nasolacrimal duct and the lacrimal fossa formed a greater angle on the right side than on the left side.^[7-12]

Author's observation showed the highest rate of patients were female and most of the females came from the middle and lower income groups, who working in the farms used wood and dried cow dung for cooking, which gave away a lot of smoke particles, which could have settled down in the conjunctive sac, entered the nasolacrimal duct through tears and in turn had blocked the nasolacrimal duct. On the other hand, considering that chronic sinusitis can be one of the causes of the nasolacrimal blockage^[16,17] and given the geography and climate of the north of Iran and the presence of allergens such as pollen, agricultural pesticides, which has an important role in sinus infection and subsequent inflammation of the nasolacrimal duct, consultation with ENT specialist is recommended to check the sinuses by ENT before surgery.

Regarding delay in diagnosis of dacryocystitis leads to some consequences to create such conjunctivitis in the patients and malignant neoplasms of the lacrimal sac, which may occur as clinical dacryocystitis.^[18] Therefore, there is a need for broader epidemiological studies in this field to assist the diagnosis and treatment, which plays an important role in reducing complications and health-care costs.

Acknowledgment

We would like to thank the Vice Chancellor for Research and Technology, Mazandaran University of Medical Sciences.

References

1. Yanoff M, Duker JS. Ophthalmology. 3rd ed. Philadelphia: Mosby Elsevier; 2009. p. 1482-7. Available from: http://www.en.wikipedia.org/wiki/Nasolacrimal_duct_obstruction. [Last accessed on 2013 Jun 14].
2. Duggal P, Chakravorty S, Azad RK, Mohan C. An epidemiological study on patients undergoing dacryocystorhinostomy. Indian J Otolaryngol Head Neck Surg 2006;58:349-51.
3. Ali MJ, Naik MN, Honavar SG. External dacryocystorhinostomy: Tips and tricks. Oman J Ophthalmol 2012;5:191-5.
4. Karim R, Ghabrial R, Lynch T, Tang B. A comparison of external and endoscopic endonasal dacryocystorhinostomy for acquired nasolacrimal duct obstruction. Clin Ophthalmol 2011;5:979-89.
5. Durvasula VS, Gatland DJ. Endoscopic dacryocystorhinostomy: Long-term results and evolution of surgical technique. J Laryngol Otol 2004;118:628-32.
6. Choi JC, Jin HR, Moon YE, Kim MS, Oh JK, Kim HA, *et al.* The surgical outcome of endoscopic dacryocystorhinostomy according to the obstruction levels of lacrimal drainage system. Clin Exp Otorhinolaryngol 2009;2:141-4.
7. Prakash R, Babu RJ, Nagaraj ER, Prashanth HV, Shah JS. Bacteriological study of dacryocystitis. J Clin Diagn Res 2012;6:652-5.
8. Badhu B, Dulal S, Kumar S, Thakur SK, Sood A, Das H. Epidemiology of chronic dacryocystitis and success rate of external dacryocystorhinostomy in Nepal. Orbit 2005;24:79-82.
9. Ferdosi AA, Mohammadrabi H, Ziaee H, Moarefian SH. The result of dacryocystorhinostomy surgery by Celicon tube and its related factors. Bina J Ophthalmol 1997;2:131-8.
10. Yang JW, Oh HN. Success rate and complications of endonasal dacryocystorhinostomy with unciformectomy. Graefes Arch Clin Exp Ophthalmol 2012;250:1509-13.
11. Knežević MM, Vlajković GP, Stojković MŽ, Rašić DM, Stanković BR, Božić MM. Comparison of postoperative pain and satisfaction after dacryocystorhinostomy in patients operated on under local and general anesthesia. Med Sci Monit 2012;18:CR265-70.
12. Gilliland G. Dacryocystitis. In: Agarwal S, Agarwal A, Apple DJ, Buratto L, Alio JL, Pandey SK, *et al.*, editors. Textbook of Ophthalmology. 1st ed. New Delhi: Jaypee Brothers Medical Publishers (P) Ltd.; 2002. p. 705-12.
13. Yoon SW, Yoon YS, Lee SH. Clinical results of endoscopic dacryocystorhinostomy using a microdebrider. Korean J Ophthalmol 2006;20:1-6.
14. Babar TF, Masud MZ, Saeed N, Khan MD. An analysis of patients with chronic dacryocystitis. Pak J Ophthalmol 2003;19:77-83.
15. Ivanišević M, Bojic L, Lešin M, Žuljan I, Bucan K, Kovacic Ž. Primary acquired nasolacrimal duct obstruction: Epidemiological analysis of 91 patients. Med JAD 2007;37:37-41.
16. Komínek P, Matoušek P, Štrympl P. Dacryocystitis as the first symptom of sinonasal carcinoma. Ophthalmology 2010;24:343-5.
17. Singh M, Jain V, Singh SP, Gupta SC. Endoscopic dacryocystorhinostomy in cases of dacryocystitis due to atrophic rhinitis. J Laryngol Otol 2004;118:426-8.

18. Woog JJ. The incidence of symptomatic acquired lacrimal outflow obstruction among residents of Olmsted County, Minnesota, 1976-2000 (an American ophthalmological society thesis). *Trans Am Ophthalmol Soc* 2007;105:649-66.

How to cite this article: Majidaee M, Mohammadi M, Sheikh Rezaee MR, Khademlu M, Heidari Gorji MA. Patients undergoing dacryocystorhinostomy surgery in northern Iran: An epidemiologic study. *Ann Med Health Sci Res* 2014;4:365-8.

Source of Support: Nil. **Conflict of Interest:** None declared.