

# Locked Twins: A Rarity

Borah T, Das A

Department Obstetrics and Gynecology, North Eastern Indira Gandhi Regional Institute of Health and Medical Sciences, Mawdiangdiang, Shillong, Meghalaya, India

**Address for correspondence:**

Dr. Tulon Borah, Department of Obstetrics and Gynecology, NEIGRIHMS, Shillong, Meghalaya - 793 018 India. E-mail: borahrtulon@gmail.com

## Abstract

Locked twins is a rare, hazardous obstetric complication. Herein, we report the rare condition of an unbooked case of locked twin that attended our labor room in late stage of labor with arrested after-coming head of the first twin, which was dead. Caesarean section was performed to save the second baby. Antenatal diagnosis of twin gestation with leading twin breech and second twin cephalic presentation raises index of suspicion of potential locked twin. Timely done caesarean delivery could have avoided the fetal death.

**Keywords:** Breech presentation, Interlocking twin, Perinatal death

## Introduction

Locked twins usually occur when the after-coming head of the first breech fetus is locked with the head of the second cephalic fetus. Of the different etiological factors, the most important are the age and parity of the mother and the size of the twins. A large pelvis with relatively small infants and decreased liquor volume following rupture of membranes are thought to be factors favoring interlocking. This complication of twin delivery occurs rarely, 1 in every 90,000 deliveries or 1 in every 1000 twin deliveries.<sup>[1]</sup> It is thus felt justifiable to report this case.

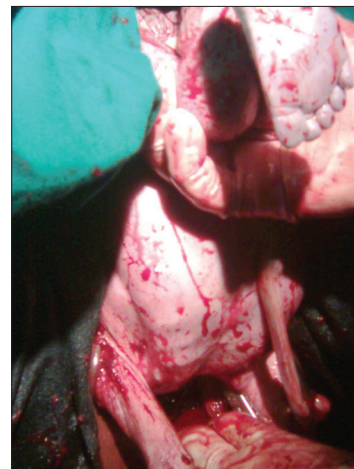
## Case Report

An unbooked primigravida aged 31 years was admitted to the labor room with arrested after-coming head of breech. The patient was not aware of her last menstrual period. On examination, her vitals were stable. Per abdominal examination revealed uterine fundal height of 28 weeks' size and a fetal heart rate of 136 beats/minute, auscultated just above the level of the umbilicus. No heart sound was found for the first baby. Vaginal examination showed the head of the second baby [Figure 1]. It was then realized that the head felt above the symphysis pubis was that of the first twin. As the locking was so tight and the second baby's fetal heart beat was still present,


lower segment caesarean section (LSCS) was performed in the interest of the surviving baby. After disimpaction of the head vaginally, the second baby weighing 1.2 kg was delivered abdominally by breech. The baby was then handed over to the pediatrician. The first baby weighing 1 kg, which was already dead, was delivered vaginally. Placental examination showed it to be a monochorionic diamniotic twin. The second baby was discharged after 2 weeks of observation in the pediatric intensive care unit. The mother had an uneventful post-operative stay in the hospital and was discharged subsequently. The patient was seen in the postnatal clinic 6 weeks later. She was well with healed abdominal wound and involuted uterus.

## Discussion

Locked twins is a rare complication of twin delivery when the first baby presents as breech and second one being in cephalic



**Figure 1:** Arrested after-coming head of the first baby of locked twin

Access this article online	
<b>Quick Response Code:</b> 	<b>Website:</b> <a href="http://www.amhsr.org">www.amhsr.org</a>
	<b>DOI:</b> 10.4103/2141-9248.105676

presentation. Predisposing factors of locking are usually small babies, large pelvis, primigravida, oligohydramnios, uterine hypertonicity, early rupture of the second sac, and monochorionic monoamniotic twins. When size of babies is large, they tend to lock above the pelvic inlet, and small twins lock after descent into the pelvis.

Locked twins can be avoided by cesarean delivery in all cases in which first baby is not vertex. However, if the first baby is already partially delivered as breech, disimpaction can be tried by pushing both heads upward out of the pelvis under anesthesia. If this cannot be done, cesarean with abdominal delivery of both fetuses may be the safest route.

Ultrasonography (USG) should be done in all twin pregnancies at term, especially when the first twin presents by breech or when the palpatory findings are obscure.

Early diagnosis of interlocking twin could be made by a repeat USG if there is a failure of descent of the first baby in presence of good uterine contraction in an adequate pelvis.

Locking of twins is usually a late second stage diagnosis when difficulty is encountered in delivering the first twin, making its survival difficult in most cases.<sup>[2]</sup> In our case, it was all the more difficult because of her being an unbooked and undiagnosed twin pregnancy with arrested after-coming head of the first twin. As locking was very tight and disimpaction not feasible, decision for LSCS was taken in spite of the dead first baby and doubtful fetal maturity. There is also a case report from

Johannesburg, South Africa, where locked twins were born vaginally after hexoprenaline sulfate, a beta-sympathomimetic drug. This was used to relax the uterus so that the fetal heads could be disimpacted.<sup>[3]</sup> A successful outcome in locked twins has also been found after applying the Zavanelli maneuver.<sup>[4]</sup>

## Conclusion

The management of locked twins must be individualized. Our case was unfortunate, not only because of the rare condition but also because of its being unbooked and presented late in labor. Fetal morbidity and mortality can be avoided in such situations by identifying the potential cases, radiological diagnosis, and timely done cesarean section.

## References

1. El Deiry SK. Two cases of locked twins. *Br Med J* 1960;1:1174-7.
2. Salmon YM. Locked twins-report of 2 cases. *Singapore Med J* 1968;9:89-91.
3. Sevitz H, Merrell DA. The use of a beta- sympathomimetic drug in locked twins. Case report. *Br J Obstet Gynaecol* 2005;88:76-7.
4. Saad FA, Sharara HA. Locked twins: A successful outcome after applying the Zavanelliman oeuvre. *J Obstet Gynaecol* 1997;17:366-7.

**How to cite this article:** Borah T, Das A. Locked twins: A rarity. *Ann Med Health Sci Res* 2012;2:204-5.

**Source of Support:** Nil. **Conflict of Interest:** None declared.