

# Unusual Cause of Asymptomatic Neck Swelling

Sir,

Carotid artery aneurysm is a rare cause of asymptomatic neck mass, which is very often misdiagnosed and underappreciated. We report a case of 57-year-old male patient presented with asymptomatic left sided neck swelling. Examination revealed a firm, non-tender, non-pulsatile 6 cm × 4 cm ellipsoid swelling with the presence of carotid bruit [Figure 1]. Computed tomography angiogram and reconstructed 3D posteroanterior imaging of the carotid artery revealed a partially thrombosed fusiform aneurysm arising at the origin of left internal carotid artery [Figure 2a and b]. The aneurysm measured 5.0 cm × 3.8 cm with calcified plaques within the left external carotid artery. He was asymptomatic and treated with aspirin (75 mg/day).

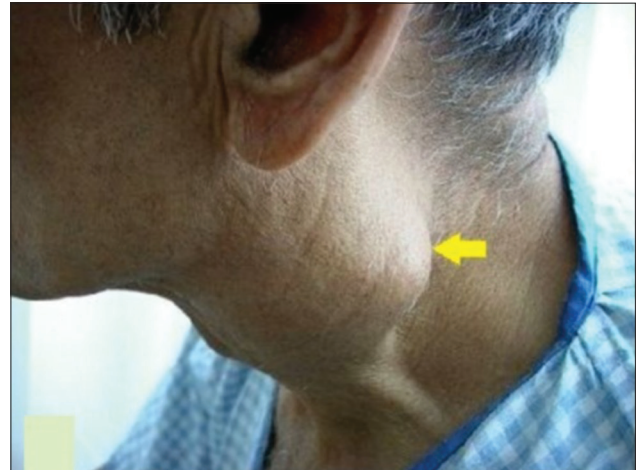
Carotid artery aneurysm is caused by trauma, atherosclerosis, connective tissue disease, vasculitis, radiation therapy and infections.<sup>[1]</sup> The treatment includes aneurysm resection with reconstruction or primary anastomosis and antiplatelet therapy.<sup>[2]</sup> Although rare, it may be considered in the differential diagnosis of a lateral neck mass even if they are non-pulsatile and needs careful attention before surgical intervention.

**Panda AK, Mahajan M<sup>1</sup>**

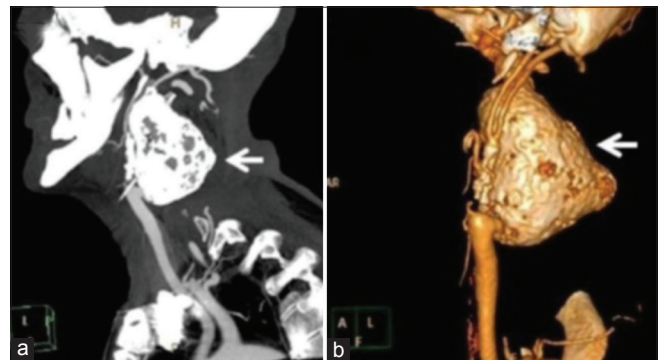
*Departments of Neurology, BLK Super Speciality Hospital, <sup>1</sup>Sir Gangaram Hospital, New Delhi, India  
E-mail: drakhilapanda@gmail.com*

## References

1. Lyons AJ, Barker CS, Flood TR. Carotid aneurysm: A rare cause of cervical swelling. *J Oral Maxillofac Surg* 1997;55:77-9.
2. Weissman JL, Johnson JT, Snyderman CH, Steed DL. Thrombosed aneurysm of the cervical carotid artery: Avoiding a retrospective diagnosis. *Radiology* 1994;190:869-71.



**Figure 1:** Photograph showing ellipsoid 6 cm × 4 cm lateral neck mass



**Figure 2:** (a) Contrast computed tomography (CT) angiography of neck vessels revealed a partially thrombosed fusiform aneurysm arising at the origin of left internal carotid artery (arrow). (b) Reconstructed 3D posteroanterior image of CT angiogram of carotid artery showing partially thrombosed fusiform aneurysm (arrow)

## Access this article online

### Quick Response Code:



Website: [www.amhsr.org](http://www.amhsr.org)

DOI:  
10.4103/2141-9248.131729