

Xanthogranulomatous Endometritis: An Unusual Pathological Entity Mimicking Endometrial Carcinoma

Makkar M, Gill MK, Singh DP

Department of Pathology, Adesh Institute of Medical Sciences and Research, Bathinda, India

Address for correspondence:

Dr. Manisha Makkar,
Department of Pathology, Adesh
Institute of Medical Sciences and
Research, Bathinda, India.
E-mail: drmanishamakkar@yahoo.co.in

Abstract

Xanthogranulomatous endometritis is an unusual pathological entity mimicking endometrial carcinoma. This shows sheets of foamy histiocytes along with other inflammatory cells. We, hereby, report a case of 45 year multigravida female with irregular menstrual history, clinically diagnosed as carcinoma and histopathologically turned out as xanthogranulomatous endometritis. So, this condition should always be dealt with caution, and pathologists and clinicians should be aware of it.

Keywords: Africa, Endometrial carcinoma, Histiocytes

Introduction

Xanthogranulomatous inflammation is a well-established histological entity characterized by xanthogranuloma which is composed of foamy histiocytes, lymphocytes, plasma cells, and variable number of foreign body giant cells. It is known to affect several organs, especially kidney, gall bladder, salivary glands, and bones.^[1] Xanthogranulomatous inflammation affecting the female genital tract is a rare entity, especially the lesions involving the endometrium. We found that only one case of xanthogranulomatous endometritis (XE) has been reported in the Indian literature.

Case Report

Herein, we report a case of a 45-year-old multigravida who presented with the complaints of continuous bleeding per vaginum for last 3 months with irregular menstrual history for 1 year. Per vaginal examination showed bulky retroverted uterus with clear bilateral fornices and healthy cervix and vagina. Laboratory investigations showed leukocytosis and low hemoglobin (8.0 gm %). On ultrasonography, she

had a bulky uterus with slight thickening of anterior wall. Endometrial thickness was 12 mm. With these findings, clinical diagnosis of endometrial hyperplasia/carcinoma was made. Subsequently, she underwent fractional curettage. Grossly, we received multiple soft tissue pieces together measuring $1.5 \times 1.0 \times 0.5$ cm. Hematoxylin and Eosin (H and E) stained sections showed proliferative endometrial glands with loose and edematous stroma, along with numerous histiocytes having foamy cytoplasm, lymphocytes, plasma cells, and areas of hemorrhage [Figures 1-3]. No evidence of malignancy was present. Serological marker for carcinoembryonic antigen was

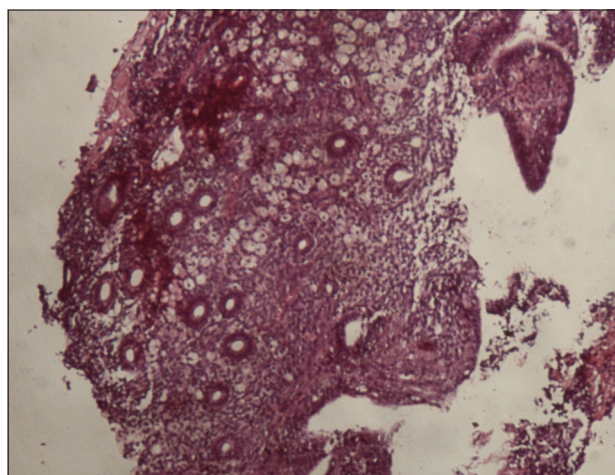


Figure 1: Photomicrograph showing numerous histiocytes having foamy cytoplasm amidst proliferative endometrial glands with loose and edematous stroma along with lymphocytes and plasma cells (H and E, $\times 100$)

Access this article online

Quick Response Code:



Website: www.amhsr.org

DOI:
10.4103/2141-9248.121222

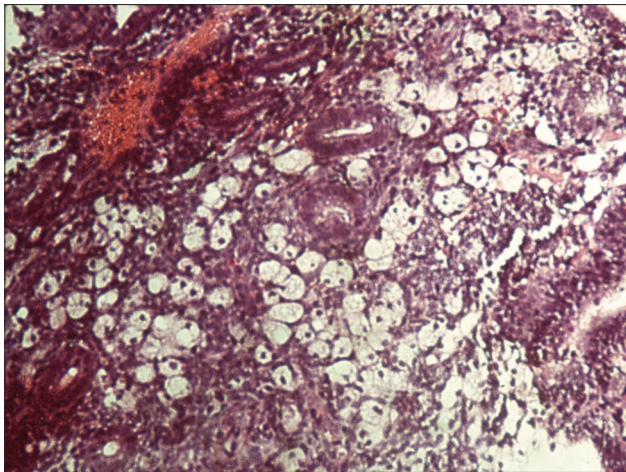


Figure 2: Photomicrograph showing many foamy histiocytes within endometrial stroma (H and E, x200)

measured to exclude malignancy. Special stains for bacteria, acid-fast bacilli (AFB), and fungi were negative. With the above findings, histological diagnosis of XE was made. Patient is currently under regular follow-up.

Discussion

XE or histiocytic endometritis is a rare entity characterized by extensive accumulation of foamy histiocytes. Russack and Lammers have reported six cases of XE, all associated with endometrial carcinoma that had been irradiated with external beam and/or intracavitary implants.

The proposed mechanism of development of XE involves a complex interaction of elements such as obstruction, inflammation, and a lipid source, as well as generation of free radicals and lipid peroxidation, which are unique to the irradiated tissues.^[2] The development of XE may be influenced by various factors, including tumor bulk or dead tumor cells due to radiation therapy or necrosis, presence of abundant amount of intrauterine hemorrhage, and cervical stenosis.^[3] Awareness of this lesion is important for pathologists and gynecologists as it may mimic malignancy.^[4] The irregular and necrotic appearance of XE may mimic carcinoma grossly, as was also reported by Ekici *et al.* in 2007. Histologically, the foamy histiocytes infiltrating the myometrium might be misdiagnosed as clear cell carcinoma or sarcoma, although the cytological and immunohistochemical detail should easily

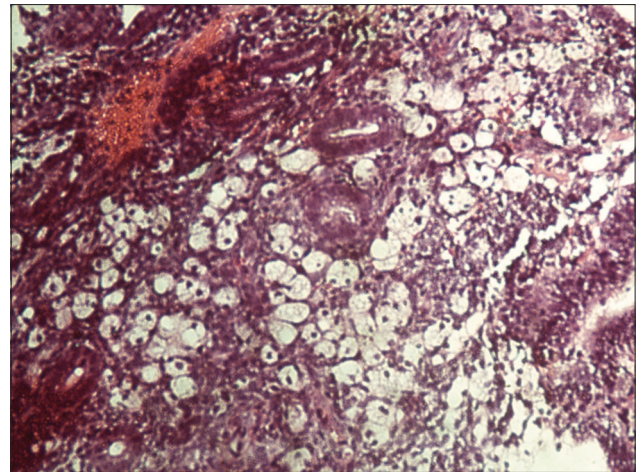


Figure 3: Photomicrograph showing many histiocytes amidst endometrial glands and stroma (H and E, x200)

resolve the issue. The possibility of coexistence of endometrial adenocarcinoma with XE is also very important point to be kept in mind by a diagnostic pathologist.^[5]

The presence of XE does not exclude the likelihood of accompanying carcinoma. Because of this possibility, sampling of entire endometrium in patient with XE should be considered.

References

1. Rosai J. Rosai and Ackerman's surgical pathology. In: Rosai J, editor. 9th ed. Missouri: Mosby; 1996. p. 1042-3.
2. Russack V, Lammers RJ. Xanthogranulomatous endometritis: Report of six cases and a proposed mechanism of development. *Arch Pathol Lab Med* 1990;114:929-32.
3. Pounder DJ, Iyer PV. Xanthogranulomatous endometritis associated with endometrial carcinoma. *Arch Pathol Lab Med* 1985;109:73-5.
4. Noack F, Briese J, Stellmacher F, Hornung D, Horny HP. Lethal outcome in xanthogranulomatous endometritis. *APMIS* 2006;114:386-8.
5. Ekici ID, Usubutun A, Kucukali T, Ayhan A. Xanthogranulomatous endometritis: A Challenging imitator of endometrial carcinoma. *Infect Dis Obstet Gynecol* 2007;2007:34763.

How to cite this article: Makkar M, Gill MK, Singh DP. Xanthogranulomatous endometritis: An unusual pathological entity mimicking endometrial carcinoma. *Ann Med Health Sci Res* 2013;3:S48-9.

Source of Support: Nil. **Conflict of Interest:** None declared.